Terri DeJohn, MD
FACEP, ABEM/UHM
Medical Director

APPLICATIONS OF HYPERBARIC MEDICINE IN THE DIABETIC PATIENT

HYPERBARIC OXYGEN Approved by CMS for Diabetic Lower Extremity Ulcers

- Approved in 2002
- Most recent addition bringing the total to 15 indications which also include:
  - Chronic refractory osteomyelitis
  - Necrotizing infections
  - Failed flaps or grafts

Diabetic Foot Ulcers

- #1 Cause of Hospitalizations in Diabetics
- Amputation Rate is 15-46 times higher
- Goal of "Healthy People 2000" is a
  40% ↓ Amputation Rate in Diabetics
- 85% of Amputations can be prevented
  with: Early detection
  Proper treatment

Risk Factors for Lower Extremity Amputation in the Diabetic Foot

- Absence of protective sensation ~50%
- Arterial insufficiency ~ 20%
- Foot deformity and callus formation
- Autonomic neuropathy
- Limited joint mobility
- Obesity
- Impaired vision
- Poor glucose control
- Poor footwear
- History of foot ulcer or previous amputation

Sensory and Autonomic Neuropathy

- Distal symmetric polyneuropathy occurs in up to 58 % of patients with longstanding disease.
- Neuropathy is present in more than 82% of diabetic patients with foot wounds

TESTING SENSATION

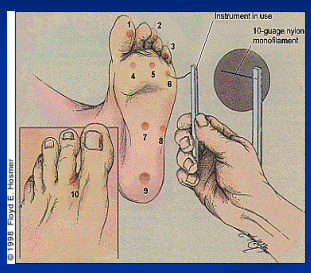

Peripheral Arterial Occlusive Disease

- 4 X more prevalent in diabetics than non-diabetics.
- Multiple Contributors:
  - Smoking
  - Hypertension
  - Hyperlipidemia

Signs and Symptoms of Peripheral Arterial Occlusive Disease

- Claudication,
- Pain occurring in the arch or forefoot at rest or during the night,
- Absent popliteal or posterior tibial pulses,
- Thinned or shiny skin,
- Absence of hair on the lower leg and foot,
- Thickened nails,
- Redness of the affected area when the legs are dependent, or "dangled,"
- Pallor when the foot is elevated.

Noninvasive Vascular Tests

Test	Abnormal value
ABI	< 0.80: abnormal < 0.45: severe Limb-threatening
TCOM	< 40 mm Hg

Transcutaneous Oxygen Monitoring

Ankle-Brachial Pressure Index (ABI)

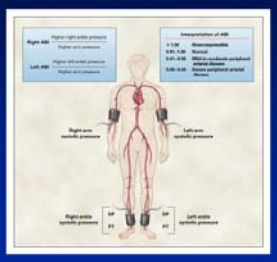

Hiatt WR, N Engl J Med 2001; 344:1608

FOOT DEFORMITY

ADA Clinical Practice Recommendations 2004

All individuals with diabetes should receive an annual foot examination to identify high-risk foot including:

- Protective sensation
- Foot structure and biomechanics
- Vascular status
- Skin integrity

Annual Foot Exams in Patients with Diabetes

- National average 55%
- Utah 72.8%

Rates for Inpatient Hospital Discharges for LEAs per 1,000 in persons with Diabetes

	U.S.	Utah
Crude Rate	6.5	3.2
Age-adjusted Rate	5.5	2.7

HOW DANGEROUS IS THIS ULCER?

PREVALENCE OF AMPUTATION

	0	1	2	3
A	Lesion Epithelialized 0%	Superficial 0%	Tendon/ Capsule 0%	Penetrates Bone/Joint 0%
B	Infection 12%	Infection 8%	Infection 24%	Infection 52%
C	Ischemia 25%	Ischemia 28%	Ischemia 26%	Ischemia 100%
D	Infection & Ischemia 50%	Infection & Ischemia 50%	Infection & Ischemia 100%	Infection & Ischemia 100%

Armstrong, Diabetes Care, 1998

SIGNS OR SYMPTOMS OF INFECTION IN THE DIABETIC

- Purulent Secretions
- 2 or more of the following

Redness	Pain	Tenderness
Induration	Warmth	Lymphangitis
Foul Smell	Gas Formation	

- Systemic Sx =↑BS, Malaise,+/- Fever or +/- ↑WBC, or ↑ESR, ↑CRP
- +MRI, Histology, or Cultures of bone.

EXPECTED HEALING OF DFU

- Curative Health Services
- 39,918 Neuropathic Wounds
- Used 20 weeks as their endpoint.
  Wounds not closed by this time often did not heal.

CHARACTERISTICS OF WOUNDS THAT HEALED

	Healed	Unhealed
Wound Size (mm^2)	133	255
Duration (months)	1	2
% Change at 4wks	30-40%	
Wound Grade		Penetrate Fat

Margolis- 10/2002

CLINICS IN INFECTIOUS DISEASE DIAGNOSIS AND TREATMENT OF DIABETIC FOOT INFECTIONS

- Optimize diabetic control
- Tissue culture and appropriate antibiotics
- Appropriate imaging to determine the extent of the infection
- Surgical consultation for debridement
- Evaluate arterial supply and consider revascularization when indicated

CLINICS IN INFECTIOUS DISEASE

DIAGNOSIS AND TREATMENT OF DIABETIC FOOT INFECTIONS

- Providing optimal wound care, in addition to appropriate antibiotic treatment of the infection, is crucial for healing.
  - Wound cleansing
  - Debridement
  - Off-loading

DIABETIC FOOT ULCER

- 54 year old Woman with a Diabetic Foot Ulcer
  - Diabetes was Uncontrolled
  - No Wound Care
  - Needed Good Wound Care - No HYPERBARICS

CLINICS IN INFECTIOUS DISEASE

DIAGNOSIS AND TREATMENT OF DIABETIC FOOT INFECTIONS

- Systematic reviews suggest that granulocyte colony-stimulating factors and systemic hyperbaric oxygen therapy may help prevent amputations.
- These treatments may be useful for severe infections or for those that have not adequately responded to therapy, despite correcting for all amenable local and systemic adverse factors.

Jun 11 2006
(7 Suppl) 212S-238S

WHEN SHOULD YOU REFER A PATIENT?

BEFORE THIS:

Referral Guidelines FOOT CARE

- HISTORY
  - Recurrent Cellulitis of LE
  - Previous Ulcers, Amputation
- PHYSICAL EXAM
  - Failure to Achieve 40% ↓ in 4 Wks
  - Signs of deep infections
  - Refractory Edema
  - Questions of Ischemia

Wound Documentation

- Measure

Feb 15: 13.7 x 2.8 x 0.1
Mar 12: 11.2 x 2.0 x 0.1

- Trace



Wound Documentation

- Measure
- Trace
- Picture

Final Pathways to Wound Healing Failure

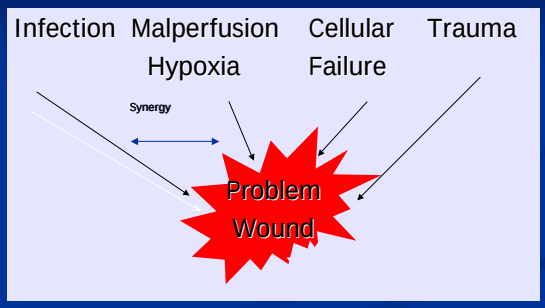

ISCHEMIA ???

Wounds with TcPO2<40 will not heal without intervention.

They need revascularization and/or HBO2 therapy

Oxygen is Required for :

- Superoxide production for intracellular bacterial killing
- Collagen deposition
- Angiogenesis
- Epithelization

Hyperbaric Oxygen Therapy (HBOT)

The delivery of 100% oxygen breathed at increased atmospheric pressure (> 1.5 ATA).

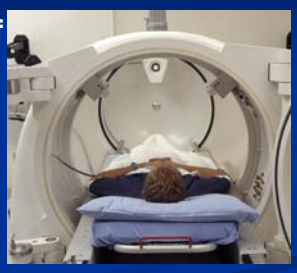

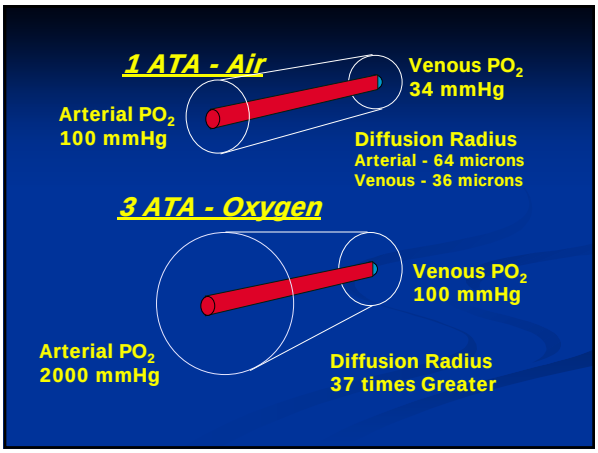

Mono-Place Chambers

Multiplace Chamber

3/20/2007

INSIDE A MULTIPLACE CHAMBER
(HMS/OXYHEAL Chamber at Lakeview Hospital)

- Compressed with Air
- 100% Oxygen delivered through an Acrylic flexible hood
- Neck Seal

Randomized Controlled Trials of HBO in DFU

Faglia, 1996	Amputations	HBO 8.6% Control 33.3%
Doctor, 1992	BKA	HBO 2/15 Control 7/15
Abidia, 2001	Healing at 12 wks	HBO 69% Control 29%
Kalani, 2002	Healing 3 yrs	HBO 76% Control 29%
	Amputations	HBO 12% Control 33%

Diabetic Foot Ulcers

- 38 Diabetic Patients studied Prospectively
  - All had TCOM < 40mm Hg
  - All responded to 100% Oxygen with TCOM > 100mm Hg or 3x Initial Value
- Treatment groups included:
  - 21 patients treated conservatively
  - 17 had HBO (40-60 treatments)

Kalani M, et al Stockholm, Sweden
J Diabetes Complications
2002;16(2):153-8

Diabetic Foot Ulcers

	Control	HBOT
Intact skin @ 3 yrs	48 %	76 %
Amputation	33 %	12 %

Kalani M, et al Stockholm, Sweden
J Diabetes Complications 2002;16(2):153-8

Physiologic Effects of HBO_2

- Vasoconstriction ⇒ ↓ Edema
- Leukocytes kill bacteria more effectively
- Collagen synthesis and cross-linking
- Endothelial cell proliferation
- Angiogenesis
- Enhancement of some antibiotic activity

HBO and Collagen Formation

Cross Linking Increases Stability

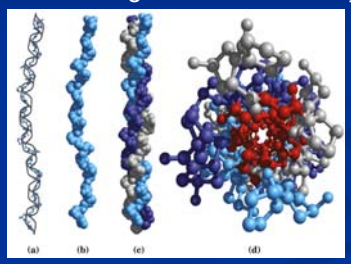

HBO and WOUND DURABILITY

WITH STANDARD WOUND CARE
- 20% No Recurrence at 3 mo.

WITH HYPERBARIC OXYGEN THERAPY
- 86% No Recurrence at 1 yr.
- 80% No Recurrence at 3 yrs.

Cianci, Wound Rep Regen 1997; (5):141-146

Diabetes & Osteomyelitis

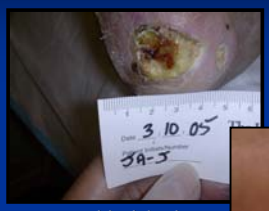

Infected Calcaneous s/p ORIF then external fixation

Options: BKA vs HBO

25 year old Diabetic

Diabetic Foot Ulcers

Presence of exposed bone should be considered diagnostic of **osteomyelitis**.

64% of Ulcers with osteo had no exposed bone.

Probability of Osteomyelitis increases with
- Less tissue between wound bed and bone.
- Longer duration of wound over bone.

Osteomyelitis

Infected Bone is Hypoxic

Normal Oxygen Tension

Healthy bone = 45mm Hg

Infected bone = 23 mm Hg

Hyperbaric Oxygen Tension

Infected bone = 30 –1200 mm

REFRACTORY OSTEOMYELITIS

COST EFFECTIVENESS OF HBOT

Complicated Refractory Osteomyelitis Cases had an average cost of $115,000.

Addition of HBOT to good surgical and antibiotic therapy reduced the cost to $20,000

(in 1987 dollars)

Strauss

J Hyperbar Med

COMPROMISED SURGICAL FLAP

72 year old Polynesian, Diabetic who had her forefoot amputated after finding tissue in her sock.

Her wound dehisced 1 month after surgery.

OXYGEN DIFFUSION through Tissue Fluid to Cells

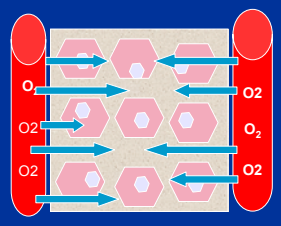

OXYGEN DIFFUSION with EDEMA

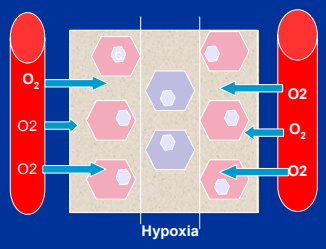

THREATENED FLAPS AND GRAFTS

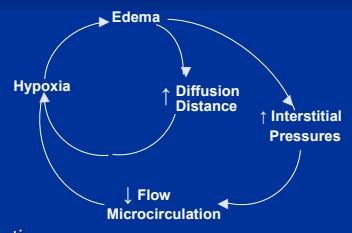

Self-Perpetuating

COMPROMISED SURGICAL FLAP

s/p 30 HBOT's

Positive Outcomes
Wound Care & Hyperbaric Medicine

27 HBO Treatments / 6 ½ Weeks

Positive Outcomes
Wound Care & Hyperbaric Medicine

Initial Evaluation

Positive Outcomes Wound Care

Indications for Hyperbaric Oxygen Therapy

INDICATION

1) Carbon Monoxide Poisoning
2) Decompression Illness ("Bends")
3) AGE (Arterial Gas Embolism)
4) Clostridial Myonecrosis (Gangrene)
5) Acute traumatic ischemia
6) Crush injury, compartment syndrome
7) Necrotizing soft tissue infections ("Flesh eating bacteria")

Indications for Hyperbaric Oxygen Therapy (continued)

8) Acute Peripheral Arterial Insufficiency
9) Compromised Skin Grafts and Flaps
10) Osteomyelitis (Refractory)
11) Radiation damage to bone
12) Radiation damage to soft tissues.
13) Cyanide Poisoning
14) Actinomycosis
15) Diabetic Foot Ulcers (Wagner grade III)

DIABETIC FOOT ULCERS AND HYPERBARIC OXYGEN THERAPY

MEDICARE REQUIRES:

- Type 1 or 2 Diabetes
- Wagner grade III or higher wound
- Failed 30 days of standard treatment
  - Correction of Vascular abnormalities
  - Optimal nutrition and diabetic control
  - Good wound care : Debridement, Dressing, Off-loading, Infection control

RECOMMENDATIONS

Hyperbaric Oxygen Therapy should be considered in

- Patients with small vessel disease not amenable to revascularization.
- Patients with clinical findings of failed wound healing or wound deterioration after LEAR
- Patients with evidence of acute ischemic compromise due to surgical and endovascular intervention

RECOMMENDATIONS

"Employing advanced wound care technologies such as HBOT in a directed and appropriate fashion can significantly enhance wound healing efforts."

Jeff Niezgoda, MD

(801) 582-4268

www.saltlakeregional.com