

# ECHINOCOCCOSIS

## ✓ DISEASE AND EPIDEMIOLOGY

### **Clinical Description:**

*Echinococcus granulosus* infections remain silent for years before the enlarging cysts cause symptoms in the affected organs. Hepatic (liver) involvement can result in abdominal pain, a mass in the hepatic area, and biliary duct obstruction. Pulmonary involvement can produce chest pain, cough, and hemoptysis (coughing up blood). Rupture of the cysts can produce fever, urticaria (hives), eosinophilia, and anaphylactic shock, as well as cyst dissemination. In addition to the liver and lungs, other organs (brain, bone, heart) can also be involved, with resulting symptoms.

*Echinococcus multilocularis* affects the liver as a slow growing, destructive tumor, with abdominal pain, biliary obstruction, and occasionally metastatic lesions into the lungs and brain.

*Echinococcus vogeli* affects mainly the liver, where it acts as a slow growing tumor; secondary cystic development is common.

### **Causative Agent:**

Human echinococcosis (hydatidosis or hydatid disease) is caused by the larval stages of cestodes (tapeworms) of the genus *Echinococcus*. *Echinococcus granulosus* causes cystic echinococcosis, the form most frequently encountered; *E. multilocularis* causes alveolar echinococcosis; *E. vogeli* causes polycystic echinococcosis; and *E. oligarthrus* is an extremely rare cause of human echinococcosis.

### **Differential Diagnosis:**

Differential diagnosis includes malignancies, amoebic abscesses, congenital cysts and tuberculosis.

### **Laboratory identification:**

#### **Antibody Detection**

Immunodiagnostic tests can be very helpful in the diagnosis of echinococcal disease, and should be used before invasive methods. However, the clinician must have some knowledge of the characteristics of the available tests and the patient and parasite factors associated with false results. False-positive reactions may occur in persons with other helminthic infections, cancer, and chronic immune disorders. Negative test results do not rule out echinococcosis because some cyst carriers do not have detectable antibodies.

Whether the patient has detectable antibodies depends on the physical location, integrity, and vitality of the larval cyst. Cysts in the liver are more likely to elicit antibody response than cysts in the lungs, and, regardless of localization, antibody detection tests are least sensitive in patients with intact hyaline cysts. Cysts in the lungs, brain, and spleen are associated with lowered serodiagnostic reactivity, whereas those in bone appear to more regularly stimulate detectable antibody. Fissuration or rupture of a cyst is

followed by an abrupt stimulation of antibodies. A patient with senescent, calcified, or dead cysts is generally found to be seronegative.

**Pathology**

Echinococcus can be identified through a excision of the cyst and examination by a pathologist.

**Treatment:**

Surgery is the most common form of treatment for echinococcosis, although removal of the parasite mass is not usually 100% effective. After surgery, medication may be necessary to keep the cyst from recurring. The drug of choice for treatment of echinococcosis due to *Echinococcus granulosus* is albendazole. Some reports have suggested the use of albendazole or mebendazole for *Echinococcus multilocularis* infections.

**Case fatality:**

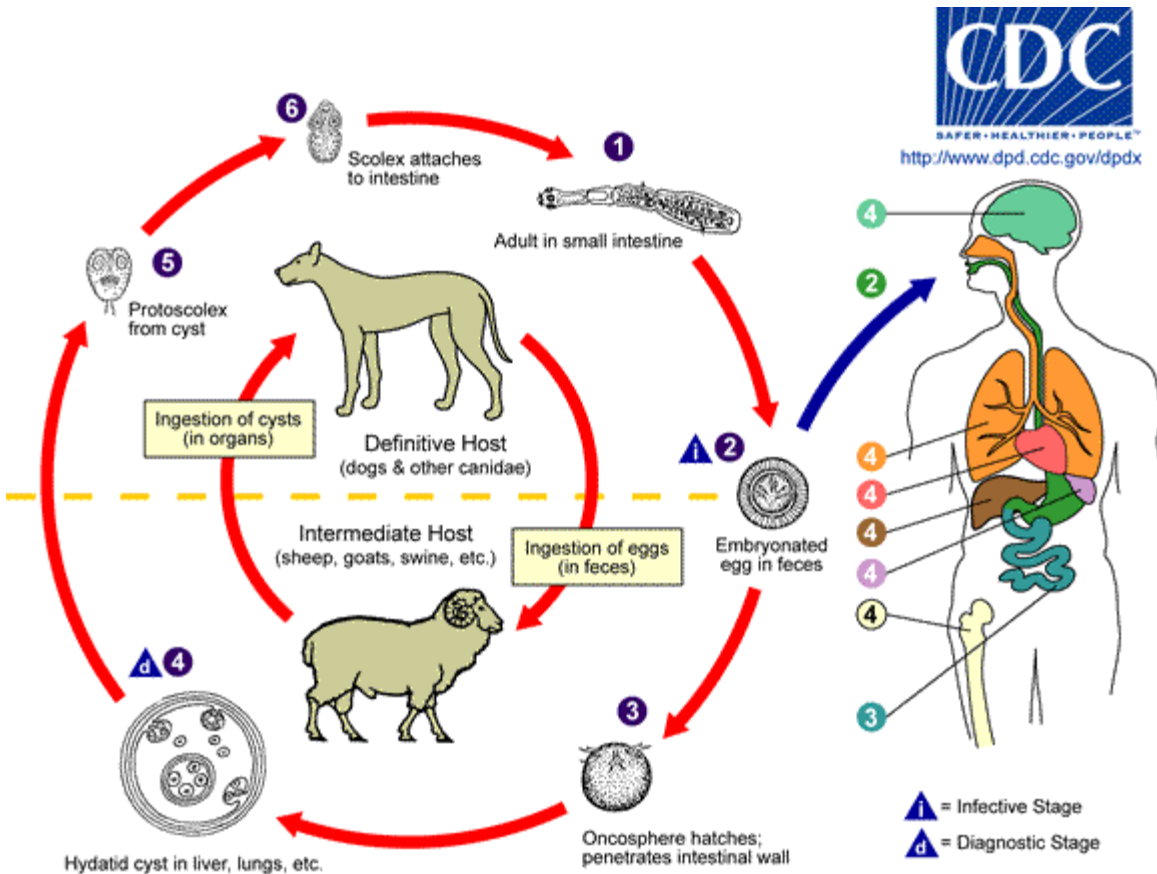
*E. multilocularis* is more fatal in untreated patients than the other strains.

**Reservoir:**

The domestic dog and other canids, definitive hosts for *E. granulosus*, may harbor thousands of adult tapeworms in their intestines without signs of infection. Felines and most other carnivores are normally not suitable hosts for the parasite. Intermediate hosts include herbivores, primarily sheep, cattle, goats, pigs, horses, camels and other animals.

**Transmission:**

**Life Cycle:**



The adult *Echinococcus granulosus* (3 to 6 mm long) **1** resides in the small bowel of the definitive hosts, dogs or other canids. Gravid proglottids release eggs **2** that are passed in the feces. After ingestion by a suitable intermediate host (under natural conditions: sheep, goat, swine, cattle, horses, camel), the egg hatches in the small bowel and releases an oncosphere **3** that penetrates the intestinal wall and migrates through the circulatory system into various organs, especially the liver and lungs. In these organs, the oncosphere develops into a cyst **4** that enlarges gradually, producing protoscolices and daughter cysts that fill the cyst interior. The definitive host becomes infected by ingesting the cyst-containing organs of the infected intermediate host. After ingestion, the protoscolices **5** evaginate, attach to the intestinal mucosa **6**, and develop into adult stages **1** in 32 to 80 days. The same life cycle occurs with *E. multilocularis* (1.2 to 3.7 mm), with the following differences: the definitive hosts are foxes, and to a lesser extent dogs, cats, coyotes and wolves; the intermediate host are small rodents; and larval growth (in the liver) remains indefinitely in the proliferative stage, resulting in invasion of the surrounding tissues. With *E. vogeli* (up to 5.6 mm long), the definitive hosts are bush dogs and dogs; the intermediate hosts are rodents; and the larval stage (in the liver, lungs and other organs) develops both externally and internally, resulting in multiple vesicles. *E. oligarthrus* (up to 2.9 mm long) has a life cycle that involves wild felids as definitive hosts and rodents as intermediate hosts. Humans become infected by ingesting eggs **2**, with resulting release of oncospheres **3** in the intestine and the development of cysts **4**, **4**, **4**, **4**, **4** in various organs.

Human infection often takes place during childhood, directly with hand-to-mouth transfer of eggs after association with infected dogs or indirectly through contaminated food, water, soil or fomites. In some instances, flies have dispersed eggs after feeding on infected feces.

Canines become infected by eating animal viscera containing hydatid cysts. Sheep and other intermediate hosts are infected while grazing in areas contaminated with dog feces containing parasite eggs.

### **Susceptibility:**

Children, who are more likely to have close contact with infected dogs and less likely to have adequate hygienic habits, are at greater risk of infection, especially in rural areas. There is no evidence that they are more susceptible to infection than are adults.

### **Incubation period:**

12 months to years, depending on number and location of cysts and how rapidly they grow.

### **Period of communicability:**

Not directly transmitted from person to person or from one intermediate host to another. Infected dogs begin to pass eggs 5 to 7 weeks after infection. Most canine infections resolve spontaneously by 6 months; adult worms may survive up to 2-3 years. Dogs may become infected repeatedly.

### **Epidemiology:**

*E. granulosus* occurs practically worldwide, and more frequently in rural, grazing areas where dogs ingest organs from infected animals. *E. multilocularis* occurs in the northern hemisphere, including central Europe and the northern parts of Europe, Asia, and North America. *E. vogeli* and *E. oligarthrus* occur in Central and South America.

Utah averages 1-2 human cases in a 10-year period.

## **PUBLIC HEALTH CONTROL MEASURES**

### **Public health responsibility:**

- 
- Investigate all suspect cases of disease and fill out and submit appropriate disease investigation forms.
- Provide education to the general public, clinicians, and first responders regarding disease transmission and prevention.
- Identify clusters or outbreaks of this disease.
- Identify sources of exposure and stop further transmission.

### **Prevention:**

1. Educate those at risk on avoidance of exposure to dog feces. Emphasize basic hygiene practices such as handwashing, washing fruits and vegetables and control of contacts with infected dogs.
2. Interrupt transmission from intermediate to definitive hosts by preventing access of dogs to potentially contaminated (uncooked) viscera through supervision of livestock slaughtering and safe disposal of infected viscera.
3. Incinerate or deeply bury infected organs from intermediate hosts.
4. Periodically treat high-risk dogs; reduce dog populations to the occupational need for them. Eliminate ownerless dogs whenever possible and encourage responsible pet ownership.
5. Field and laboratory personnel must observe strict safety precautions to avoid ingestion of tapeworm eggs.

### **Chemoprophylaxis:**

None.

### **Vaccine:**

A human vaccine is currently in development.

### **Isolation and quarantine requirements:**

None

## **CASE INVESTIGATION**

### **Reporting:**

- Report all suspect and confirmed cases of Echinococcosis.

### **Echinococcosis (Utah – 2007)**

#### **Clinical description**

*Echinococcus granulosus* infections remain silent for years before the enlarging cysts cause symptoms in the affected organs. Hepatic involvement can result in abdominal pain, a mass in the hepatic area, and biliary duct obstruction. Pulmonary involvement can produce chest pain, cough, and hemoptysis. Rupture of the cysts can produce fever, urticaria, eosinophilia, and anaphylactic shock, as well as cyst dissemination. In addition to the liver and lungs, other organs (brain, bone, heart) can also be involved, with resulting symptoms. *Echinococcus multilocularis* affects the liver as a slow growing, destructive tumor, with abdominal pain, biliary obstruction, and occasionally metastatic lesions into the lungs and brain. *Echinococcus vogeli* affects mainly the liver, where it acts as a slow growing tumor; secondary cystic development is common.

#### **Laboratory criteria for diagnosis**

- Suspicion on clinical grounds or upon screening

- Confirmation by imaging (US, CT, X-ray, etc.) and identification of characteristic or suspicious cyst structures
- Confirmation by detection of specific antibodies with immunodiagnostic tests (ELISA, IFAT, immunoblot, detection of arc 5 antibodies, etc.)
- Diagnostic puncture may be considered, if it is not contraindicated
- Material obtained by biopsy puncture or surgery can be examined: hydatid fluid for *Echinococcus* protoscoleces or hooks; protoscoleces for DNA by PCR; antigen from sterile cysts, and cyst wall material for characteristic structures by histology. In many cases, a diagnosis can be made by detecting the characteristic structure and size of *E. granulosus* cysts visualized by various imaging techniques, including ultrasonography (US), computed tomography (CT) standard radiology (X-ray), and magnetic resonance imaging (MRI) in specialized centers.

### **Clinical case definition**

Clinical diagnosis is based on signs and symptoms compatible with a slowly growing tumor, a history of residence in an endemic area, along with association with canines.

### **Case classification**

*Confirmed:*

A clinically compatible illness that is laboratory-confirmed.

### **Case Investigation Process:**

- Fill out morbidity form
- Verify case status.
- Fill out disease investigation form.
- Determine whether patient had travel/exposure history consistent with acquisition of disease in Utah or elsewhere.
- If patient acquired disease in Utah, identify the source of transmission and eliminate it.

### **Outbreaks:**

More than one case in an area would be considered an outbreak.

### **Identification of case contacts:**

None.

### **Case contact management:**

None..

## REFERENCES

Centers for Disease Control, Case Definitions for Infectious Conditions Under Public Health Surveillance. MMWR 46 (RR-10), 1997.1

Control of Communicable Diseases Manual (18<sup>th</sup> Edition), Heymann, D.L., Ed; 2004.

Red Book: 2003 Report of the Committee on Infectious Diseases (26<sup>th</sup> Edition), Larry K. Pickering MD, Ed; 2003.

Lightowers MW, Gottstein B. Echinococcosis/hydatidosis: antigens, immunological and molecular diagnosis. In: Thompson RCA, Lymbery AJ, eds. *Echinococcus* and hydatid disease. Wallingford, UK: CAB International, 1995; 355-410.

WHO/OIE Manual on Echinococcosis in Humans and Animals: a Public Health Problem of Global Concern, Edited by J. Eckert, M.A. Gemmell, F.-X. Meslin and Z.S. Pawłowski Aetiology